

# Venous Leg Ulcer treated with a silicone foam dressing

Bernd von Hallern, DGKP, Praxis Dr. R.v.d. Daele

## Introduction

A patient with a recurring venous leg ulcer over the last 40 years. The wound occurred for the first time after a fracture of the left lower leg. A thrombosis in the leg occurred in the postoperative phase after the fracture.

The leg ulcer has now been present for 20 months without any wound progression.

## Patient



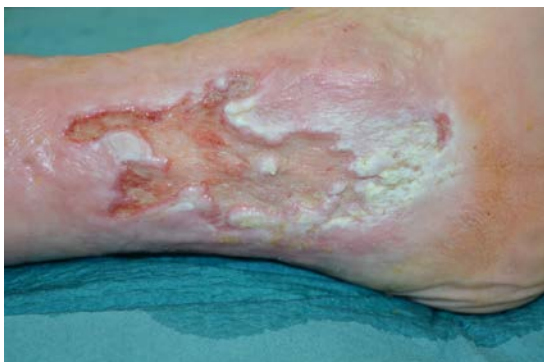87 years old patient who lives at home with some restriction on mobility. The wound size is 145x65mm and 4 mm deep. Location of the wound is on inner side of the left leg.

The wound is managed with a super absorber and foam dressing. The dressing is changed every two days. Maceration is present on both the wound edge and the periwound skin.

Compression therapy with compression bandages is part of the protocol of care.



## Initial wound assessment



<b>Size of wound</b>	Length	145	mm
	Width	65	mm
	Depth	4	mm

For tissue type and exudate, write findings  
 For others, mark "x" for positive findings from assessment,  
 and mark "0" if not present

**Wound bed assessment**

- Tissue type: Sloughy
- Exudate: Medium
- Infection:

**Wound edge assessment**

- Maceration:
- Dehydration:
- Undermining:
- Thickened/rolled edges:

**Periwound skin assessment**

- Maceration:
- Excoriation:
- Dry skin:
- Hyperkeratosis:
- Callus:
- Eczema:

**Management goals**

Mark "x" for all appropriate management goals

**Wound bed assessment**

**Management goals**

- Remove non-viable tissue:
- Manage exudate:
- Manage bacterial burden:
- Rehydrate wound bed:
- Protect granulation/epithelial tissue:

**Wound edge assessment**

**Management goals**

- Manage exudate:
- Rehydrate wound edge:
- Remove non-viable tissue:
- Protect granulation/epithelial tissue:

**Periwound skin assessment**

**Management goals**

- Manage exudate:
- Protect skin:
- Rehydrate skin:
- Remove non-viable tissue:

## Treatment

At the start of the treatment the wound size was 151x65x4mm. Compression therapy was part of the protocol of care

At the beginning of the treatment, mechanical debridement was carried out at every dressing change and a wound rinsing solution was used. The wound was left open for approximately 30 minutes to remove excess exudate. After reduction of the maceration a skin barrier was used and then Biatain Silicone was applied.

The next change was dressing was after 2 days and the macerated areas of the wound edge and periwound skin had improved

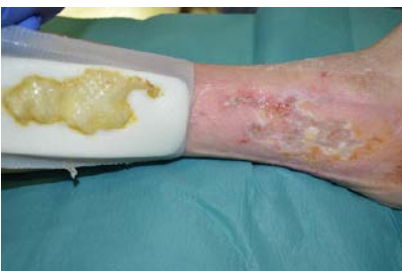After 14 days the wound was clean with moderate levels of exudate. The interval of the dressing change from day 1-14 was 3 days but was changed to every 2 days due to the amount of exudate. During the treatment, granulation tissue was observed and a skin barrier was no longer needed. Biatain Silicone was used alone for exudate management and protected the wound edge and periwound skin from maceration.

## Results

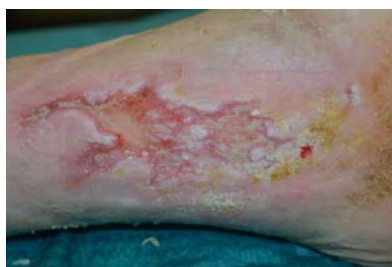Biatain Silicone provided good exudate management and conformability to the wound bed and protected the wound edge and periwound skin from maceration. New granulation tissue was observed and the wound size was reduced.

The change of the dressings have to be adapted according the amount of the exudate to avoid too much moisture to the wound and the periwound skin. For the wound bed, conforming dressings with a vertical absorption of the exudate can not only prevent maceration of the wound edge and the periwound but can also reduce the risk of infection.

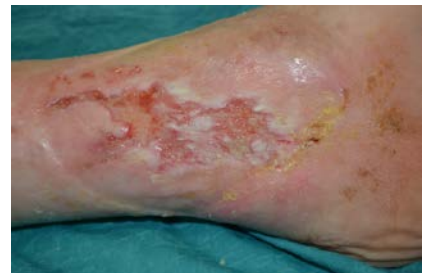The wound was completely healed after three months.



Day 2



Day 14

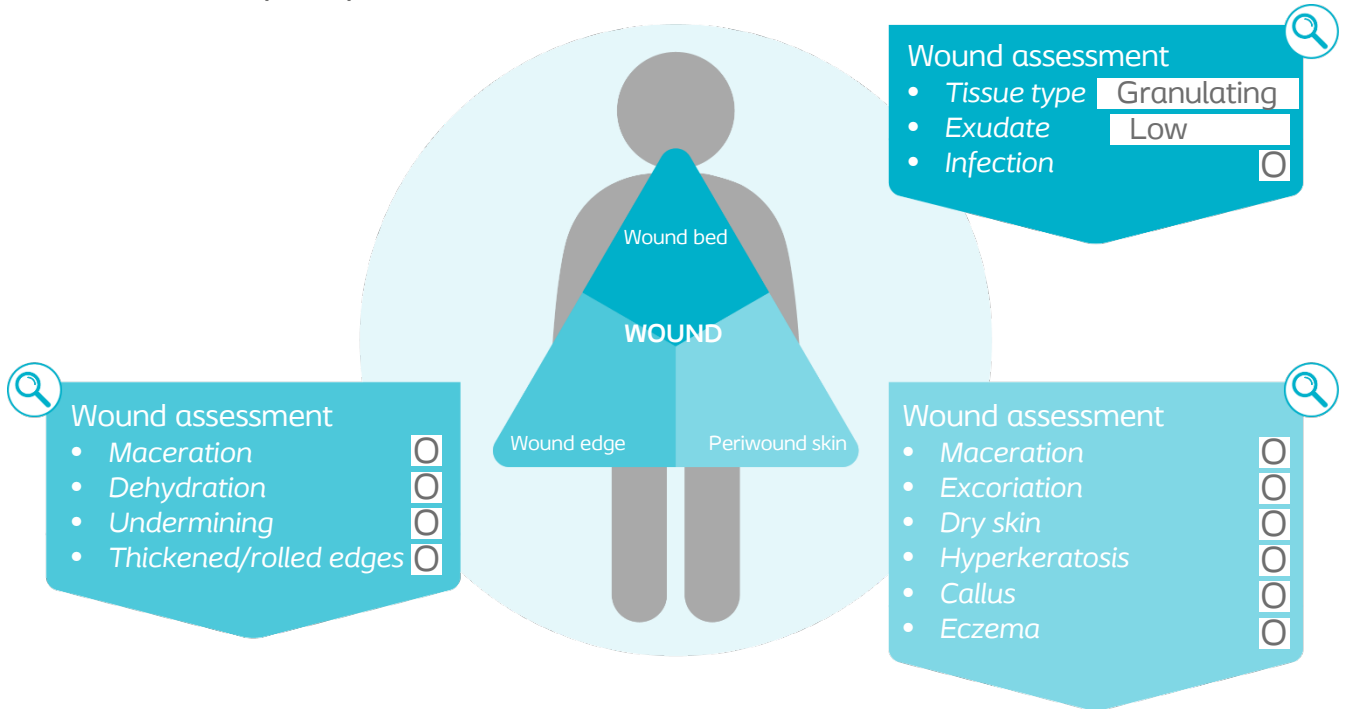


Day 30

## Reassessment of the wound at the end of case period

For tissue type and exudate, write findings

For others, mark "x" for findings from assessment, and mark "0" if not present



## Conclusion

The conformability of Biatain Silicone in combination with the soft silicone adhesive allowed good adhesion even on macerated areas of the wound edge and periwound skin.

No additional wound care products was used during the treatment and dressing change intervals was every three days.