


# Treatment of a postoperative abdominal wound with a silicone foam dressing

Bernd von Hallern DGKP, Praxis Dr. R.v.d.Daele Germany

## Introduction

Patient with cancer of the uterus, which lead to removal of uterus and both ovaries via a laparotomy incision. After an initial complication free postoperative period, a wound dehiscence occurred after three weeks.

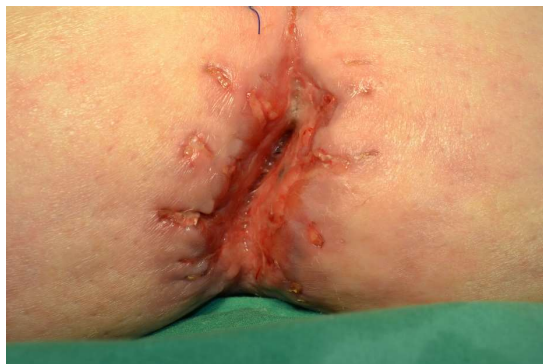## Patient



68-year-old obese and mobile female patient with a learning disability. She does not smoke or drink alcohol. No known Co-morbidities and lives in her home and works in a facility for adults with learning disability. Wound suture dehiscence occurred after three weeks, followed by a deep infection which was developed over the whole, approximately 350 mm long surgical wound. The wound was initially managed with NPWT. A closure by secondary intention took place after 14 days. In the distal wound pole (6 on the clock) a wound dehiscence re-occurred. After removing a number of sutures and performing debridement, wound management was performed outside of the hospital.

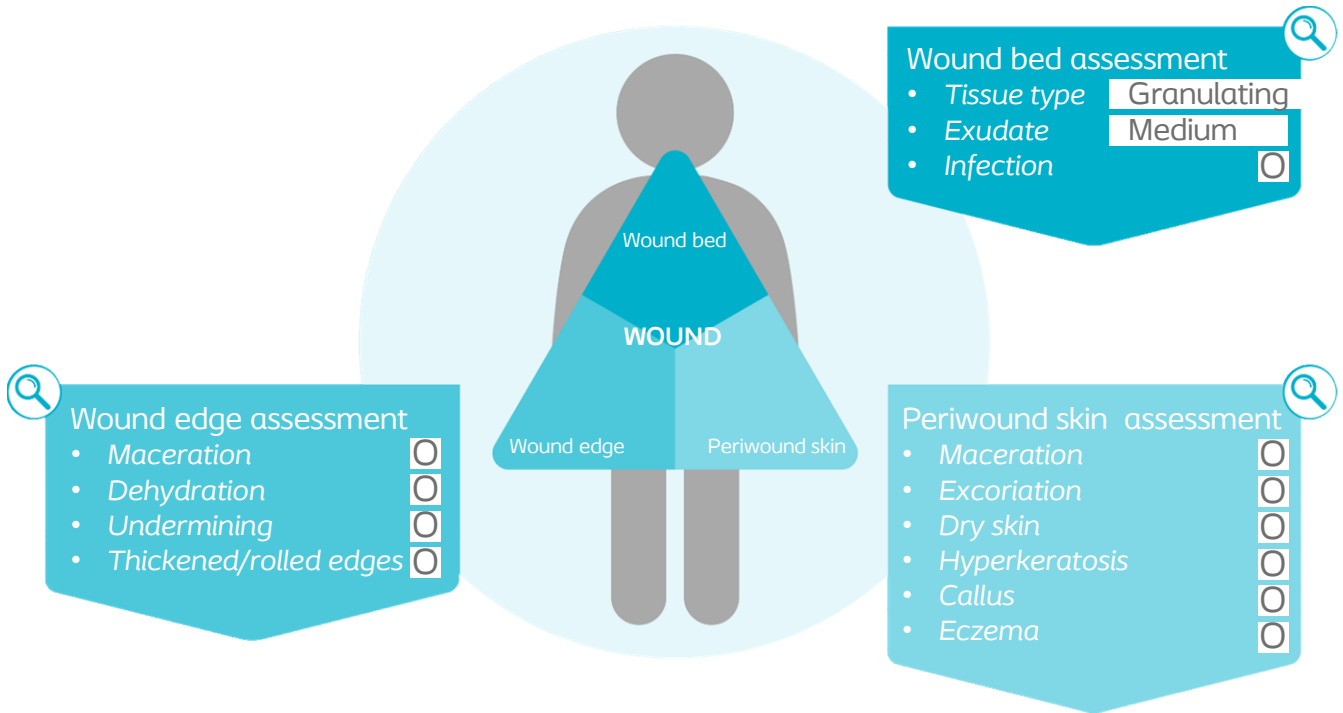


## Initial wound assessment



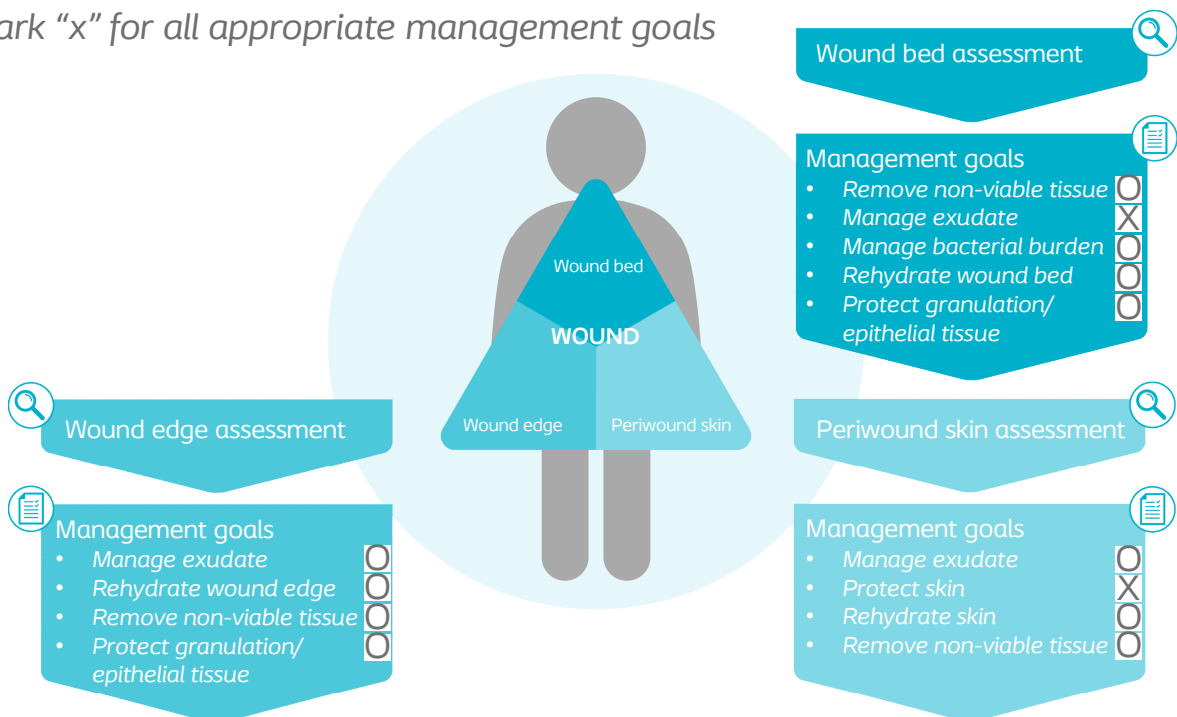
<b>Size of wound</b>	Length	80	mm
	Width	22	mm
	Depth	12	mm

For tissue type and exudate, write findings  
 For others, mark "x" for positive findings from assessment,  
 and mark "0" if not present



**Management goals**

Mark "x" for all appropriate management goals



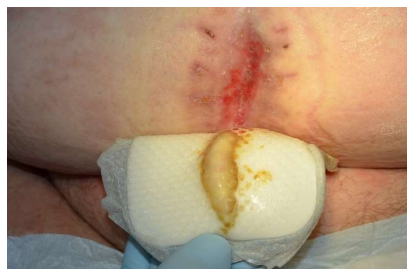## Treatment

At the beginning of the wound management, the wound was opened at the lower end of the wound. It was then cleansed and rinsed with Ringer solution. Biatain Silicone was used to cover the wound and to manage the exudate. Due to the obesity which resulted in belly folds, there were some challenges in applying the dressing. The wound was exuding moderately and the first dressing change was done after 24 hours. The excellent absorption capacity of the foam dressing then allowed a 2-day interval for dressing change. No maceration at the wound edge or periwound skin was observed. After 14 days, the wound size had been reduced to 55 x 12mm by contraction, granulation and epithelialization. The depth of the wound was 4 mm. The dressing change intervals could then be extended to 3-4 days due to only small levels of exudate.

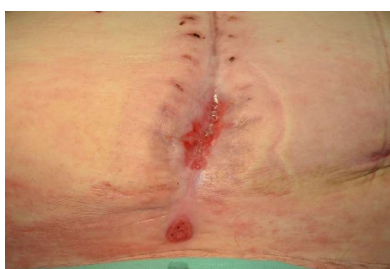On day 30, the wound was closed.

## Results

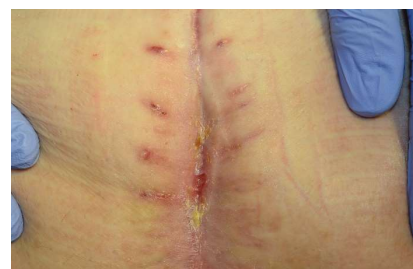Despite the challenging location amongst the skin folds, it was easy to apply Biatain Silicone. The dressing was able to conform rapidly into the wound cavity. The wound edge and periwound skin were successfully protected against the often very aggressive exudate. The dressing ensured good skin adhesion and painless removal. A wound filler was not needed for this wound. The patient appreciated the possibility to take showers, the dressing stayed in place and did not fall off.



Day 3



Day 14

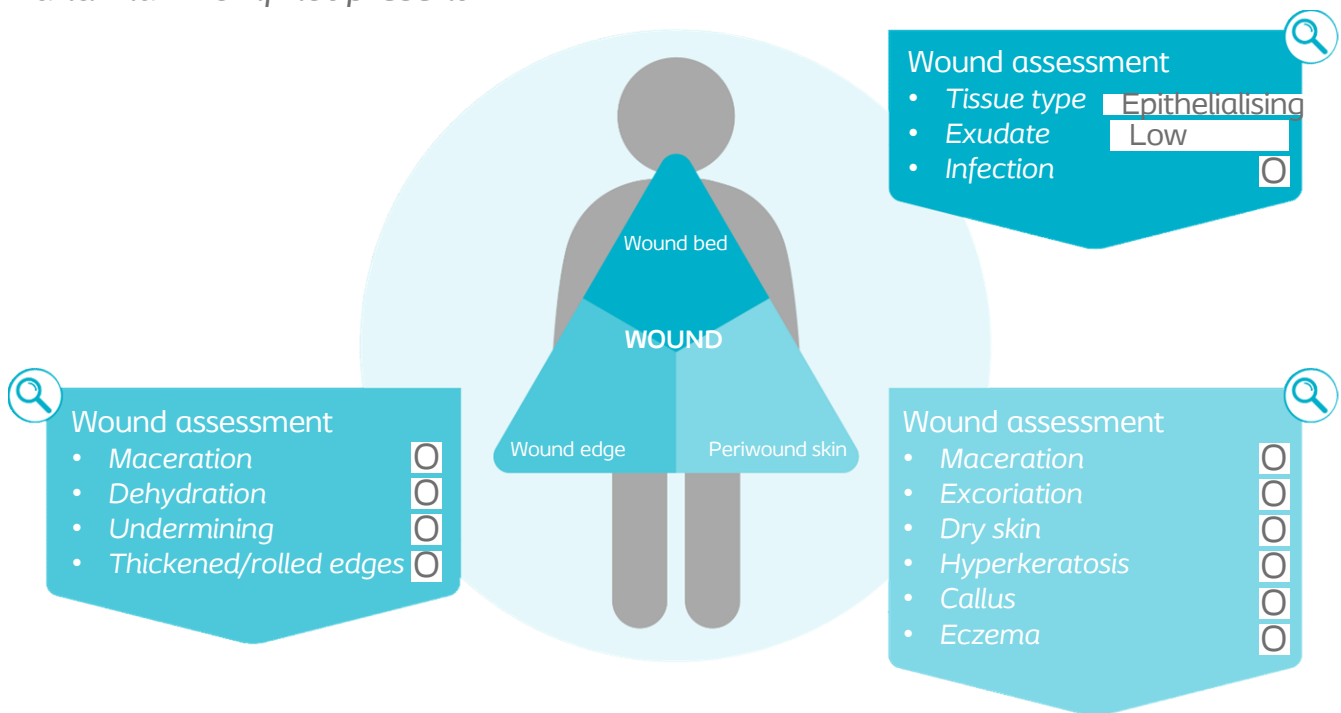


Day 30

## Reassessment of the wound at the end of case period

For tissue type and exudate, write findings

For others, mark "x" for findings from assessment, and mark "0" if not present



## Conclusion

The high absorption capacity of Biatain Silicone, combined with longer dressing change intervals, and absence of an additional wound filler, resulted in cost savings for every dressing change. The dressing protected the newly formed granulation tissue, despite skin folds being present. No maceration of the wound edge or periwound skin was observed and it did not create any therapy interruption and therefore the potential risk of secondary infections was reduced.